

Introduction:

Neuropathic osteoarthropathies are skeletal changes that occur in weight bearing joints secondary to loss of sensation. J.-M. Charcot in 1868¹, whose work described the progress of joint degeneration and connected them with spinal cord lesions. The eponymous "Charcot joint" is associated with a number of neurological conditions that may disrupt sensory input such as neurosyphilis, diabetes mellitus, leprosy, syringomyelia, and chronic alcoholism¹. However, there is little information in the paleopathological literature describing Charcot knee in dry-bone and for establishing possible differential diagnoses in paleopathological investigations. Here, we present a case study of HTH 1944 an adult male (76-79 years) with an identified Charcot knee joint from the Hamann-Todd Osteological Collection.

Skeletal Findings:

- Bony ankylosis, likely following joint subluxation, of the right knee joint with fixation of the patella (Fig. 1).
- Degradation of femoral and tibial articular surfaces of right knee joint. Lateral condyles appear to be largely destroyed and medial condyles exhibit degradation and surface expansion resulting in a flat appearance (Fig. 3 and 4). The medial tibial condyle also exhibits subchondral cysts.
- Cloaca present on both the femur and the tibia (Fig. 1 and Fig. 2).
- Femur exhibits predominantly sclerotic bone deposition, with a majority occurring on the distal half of the bone. Tibia exhibits striated periosteal new bone formation, predominantly sclerotic, along the proximal half of the tibia.



Figure 2: Lateral radiograph of right knee joint. Cloaca are circled in red.

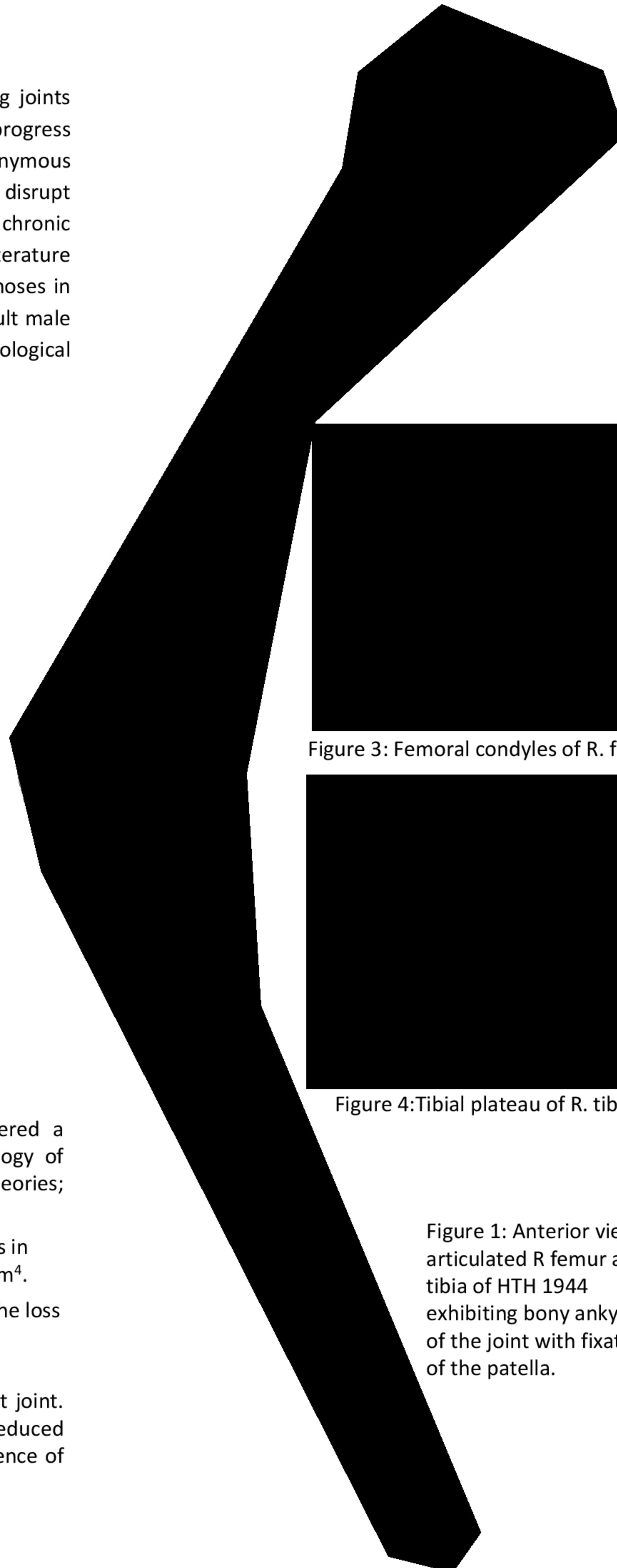


Figure 3: Femoral condyles of R. femur.




Figure 4: Tibial plateau of R. tibia.

Figure 1: Anterior view of articulated R femur and tibia of HTH 1944 exhibiting bony ankylosis of the joint with fixation of the patella.

Differential Diagnosis:

Table 1: Characteristic Features of Proposed Differential Diagnoses⁵

	Charcot Joint	Secondary Traumatic Osteoarthritis	Non-Specific Septic Arthritis
Predominant nature of lesions	<ul style="list-style-type: none"> • Destructive (during microtrauma and inflammation) • Proliferative (during repair and remodeling) 	<ul style="list-style-type: none"> • Destructive 	<ul style="list-style-type: none"> • Destructive
Lesion presentation	<ul style="list-style-type: none"> • Rounded surface and marginal osteophytes (due to the reincorporation of bone fragments) • Subchondral cysts • If immobilized bony ankylosis is likely • Subluxation and hyper-extension of joint 	<ul style="list-style-type: none"> • Eburnation • Proliferated osteophytes on the articular surfaces. 	<ul style="list-style-type: none"> • Joint degradation typically begins at the joint margins with eventual involvement of the whole joint surface. • This results in a rounded appearance on the destructive edges of joint surfaces.
Most common joint involvement	<ul style="list-style-type: none"> • Dependent on underlying neuropathy. 	<ul style="list-style-type: none"> • Knee joints (weight bearing) most commonly impacted by OA 	<ul style="list-style-type: none"> • Lower limb • Knee involvement is often associated with trauma that results in direct pathogen introduction to the joint capsule.
Fracture Patterns	<ul style="list-style-type: none"> • vertical fractures with irregular and exuberant bony callus formation 	<ul style="list-style-type: none"> • Stress fracture of the proximal tibia (in this case) 	<ul style="list-style-type: none"> • No associated fracture pattern
Clinical presentation of Pain	<ul style="list-style-type: none"> • Reduced pain sensation or no pain sensation accompanied by joint warmth. 	<ul style="list-style-type: none"> • Pain sensation variable 	<ul style="list-style-type: none"> • Severe pain sensation with accompanying fever.

Discussion and Conclusions:

In contrast to paleopathological literature, which suggests radiological findings are predictable⁶, the Eichenholtz classification system for Charcot joints has been heavily criticized as it is identical to the physiological phases of fracture healing^{7,8}. This ambiguity in differentiating fractures caused to neuroarthropathic bone degradation and those related to trauma can make differentiating Charcot joint formations from instances of repeated joint trauma with secondary traumatic osteoarthritis.

As the term "Charcot joint" implies a neurological loss of sensation, which cannot be observed osteologically, the authors encourage caution when using this term in paleopathology.

Acknowledgements:

The authors would like to thank the Cleveland Museum of Natural History and Christine Bailey for access to the Hamann-Todd Osteological Collection and permission to present this research.

References:



As a result of this uncertainty there is still no reliable test for diagnosing a Charcot joint. Instead clinicians must rely on the patterning of clinical findings, such as swelling, reduced sensation, and heat associated with the affected joint, as well as radiographic evidence of progressive joint degeneration called the Eichenholtz stages^{3,4}.